

A PROPOSED MECHANISM OF EMOTION

JAMES W. PAPEZ, M.D.

ITHACA, N. Y.

The work of Cannon,¹ Bard,² Penfield,³ Ranson⁴ and others has greatly advanced knowledge of the functions of the hypothalamus. In the light of these researches the connections of the hypothalamus to the medial wall of the cerebral cortex gain a new significance. The following discussion presents some anatomic, clinical and experimental data dealing with the hypothalamus, the gyrus cinguli, the hippocampus and their interconnections. Taken as a whole, this ensemble of structures is proposed as representing theoretically the anatomic basis of the emotions.

It is generally recognized that in the brain of lower vertebrates the medial wall of the cerebral hemisphere is connected anatomically and integrated physiologically with the hypothalamus and that the lateral wall is similarly related to the dorsal thalamus (Herrick⁵). These fundamental relations are not only retained but greatly elaborated in the mammalian brain by the further development of the hippocampal formation and the gyrus cinguli in the medial wall and of the general cortex in the lateral wall of each cerebral hemisphere.

The main steps in the phyletic history of these structures are clearly represented in the various classes of vertebrates. It is not surprising, therefore, to find that the literature on this fascinating subject presents on the whole a congruent account. Step by step, the structures of the medial wall become differentiated into the hippocampal formation, which

1. Cannon, W. B.: The James-Lange Theory of Emotion: A Critical Examination and an Alternative Theory, *Am. J. Psychol.* **39**:10-124, 1927; Again the James-Lange and the Thalmic Theories of Emotion, *Psychol. Rev.* **38**:281-295, 1931.

2. Bard, P.: (a) The Central Representation of the Sympathetic Nervous System as Indicated by Certain Physiologic Observations, *Arch. Neurol. & Psychiat.* **22**:230-246 (Aug.) 1929; (b) Emotion: I. The Neuro-Humoral Basis of Emotional Reactions, in Murchison, C. A.: A Handbook of General Experimental Psychology, Worcester, Mass., Clark University Press, 1934, chap. 6, pp. 264-311.

3. Penfield, W.: Wesley M. Carpenter Lecture: Influence of the Diencephalon and Hypophysis upon General Autonomic Function, *Bull. New York Acad. Med.* **9**:613-637, 1933, *Canad. M. A. J.* **30**:589-598, 1934.

4. Ranson, S. W.: The Hypothalamus: Its Significance for Visceral Innervation and Emotional Expression, *Tr. Coll. Physicians Philadelphia* **2**:222-242, 1934.

5. Herrick, C. J.: Morphogenesis of the Brain, *J. Morphol.* **54**:233-258 (March 5) 1933.

establishes the first efferent connection of the cortex, namely, the fornix, with the hypothalamus, and as the adjacent cingular cortex appears, it receives, per contra, an afferent connection from the hypothalamus. Step by step, the lateral wall above the pyriform cortex becomes differentiated into the lateral nonolfactory cortex, which through the medium of the internal capsule maintains its afferent and recurrent connections with the nuclei of the dorsal thalamus. The histories of the two walls of the hemispheres owe their disparity and distinctive structure to two totally different kinds of integration—the hippocampus and the cingular cortex participating in hypothalamic activities and the lateral cortex in the general sensory activities mediated by the dorsal thalamus. It is also noteworthy that in both systems two way connections exist between the cortical and the thalamic level.

The account which follows will be concerned chiefly with the reciprocal connections which exist between the hypothalamus and the gyrus cinguli and hippocampus. Its chief purpose is to point out that these connections may mediate by means of the cortical circuit the important function commonly called emotion.

The term "emotion" as commonly used implies two conditions: a way of acting and a way of feeling. The former is designated as emotional expression; the latter, as emotional experience or subjective feeling. The experiments of Bard^{2a} have demonstrated that emotional expression depends on the integrative action of the hypothalamus rather than on that of the dorsal thalamus or cortex, since it may occur when the cerebral hemispheres and the dorsal thalamus are totally removed. For subjective emotional experience, however, the participation of the cortex is essential. Emotional expression and emotional experience may in the human subject be dissociated phenomena. Hence, emotion as a subjective state must be referred to the higher psychic level. Concerning the theory of emotion based on diencephalic processes, Bard^{2b} wrote:

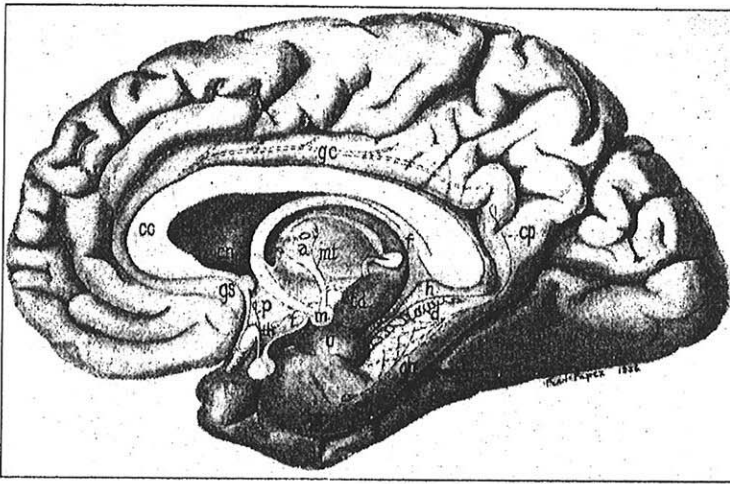
As we have seen, every relevant experimental fact points away from the periphery and directly toward the brain as the site of the processes which determine whether or not a stimulus shall give rise to emotional feeling. What is the nature and the locus of these all-important central processes?

Cannon^[1] (1927, 1931) and also Dana^[6] (1921) have proposed the theory that emotion results from the action and reaction of the cerebral cortex and the diencephalon. This theory, unlike the James-Lange theory, has considerable experimental support and takes into account anatomical and physiological facts ignored by the older view. First of all, there is the evidence that at the base of the diencephalon are located the neural patterns responsible for emotional behavior, mechanisms capable of independent discharge but normally held in check by the cerebral cortex. At the same time the cerebral cortex is the immediate site of emotional consciousness, and, as we have seen, emotional experience and emotional

6. Dana, C. L.: The Anatomic Seat of the Emotions: A Discussion of the James-Lange Theory, *Arch. Neurol. & Psychiat.* 6:634-639 (Dec.) 1921.

expression may be dissociated by disease or surgical intervention. But we know that thalamic processes are a source of affective experience, that bodily sensations such as are sometimes associated with emotion may be thalamic in origin. Well-established anatomical facts show that, with the possible exception of the olfactory, all sensory impulses are interrupted at the thalamic level before gaining the cerebral cortex, and Head's (1920) studies suggest how there may be regrouping of corticopetal impulses in the thalamus. Cannon's theory has its basis in these facts and it proposes that, at the same time that the diencephalon discharges downward the motor impulses which produce the emotional behavior, it discharges upward to the cortex impulses which throw into action the processes which underlie emotional consciousness.

In order to make clear at the outset the general anatomic picture which I wish to propose as the probable corticothalamic mechanism of emotion,



Medial view of the right cerebral hemisphere, showing the hippocampus and its connection with the mamillary body through the fornix and also the connections of the mamillary body to the anterior thalamic nuclei and thence to the cortex of the gyrus cinguli. In this specimen an unusually large exposed (nude) hippocampus is seen.

Abbreviations

<i>a</i> , anterior nucleus	<i>h</i> , hippocampus nudus
<i>ab</i> , angular bundle	<i>m</i> , mamillary body
<i>cn</i> , caudate nucleus	<i>mt</i> , mamillothalamic tract
<i>cc</i> , corpus callosum	<i>p</i> , pars optica hypothalami
<i>cp</i> , cingulum posterius	<i>pr</i> , pyriform area
<i>d</i> , gyrus dentatus	<i>sb</i> , subcallosal bundle
<i>f</i> , fornix	<i>t</i> , tuber cinereum
<i>gc</i> , gyrus cinguli	<i>td</i> , tractus mamillotegmentalis
<i>gh</i> , gyrus hippocampi	<i>th</i> , tractus hypophyseus
<i>gs</i> , gyrus subcallosus	<i>u</i> , uncus

a diagram has been constructed, showing its main features (figure). I shall start with the hypothalamus, the three parts of which are illustrated. The pars optica is connected through the infundibulum with the pars neuralis of the hypophysis. The tuber cinereum is connected downward with the lower sympathetic centers. In the human brain a large tract can be seen passing down, ventral to the red nucleus. The pars mamillaris is connected in an efferent way to the cortex of the gyrus cinguli. The pars mamillaris also receives afferent connections from several other sources, the most prominent being the fornix from the hippocampal formation.

As the figure shows, it is the mamillary body which bears the main hypothalamic relations to the cerebral cortex. This is a two way connection in the nature of a circuit through the cerebral cortex, at the upper level, and through the mamillary body, at the hypothalamic level. In this circuit impulses may be incited at two points: the cerebral cortex and the hippocampal formation and then down by way of the fornix to the mamillary body. From this they would pass upward through the mamillothalamic tract, or the fasciculus of Vicq d'Azyr, to the anterior nuclei of the thalamus and thence by the medial thalamocortical radiation (in the cingulum) to the cortex of the gyrus cinguli.

The central emotive process of cortical origin may then be conceived as being built up in the hippocampal formation and as being transferred to the mamillary body and thence through the anterior thalamic nuclei to the cortex of the gyrus cinguli. The cortex of the cingular gyrus may be looked on as the receptive region for the experiencing of emotion as the result of impulses coming from the hypothalamic region, in the same way as the area striata is considered the receptive cortex for photic excitations coming from the retina. Radiation of the emotive process from the gyrus cinguli to other regions in the cerebral cortex would add emotional coloring to psychic processes occurring elsewhere. This circuit would explain how emotion may arise in two ways: as a result of psychic activity and as a consequence of hypothalamic activity.

The hypothalamus is accessible to both visceral and somatic sensory impressions from many peripheral sources, and it is well known that emotional coloring, or affect, may be associated with all sorts of sensory experiences of bodily and receptor origin. Most of the afferent receptor systems evoke sensations with characteristic qualities, perceptions, etc., which at the conscious level are accompanied by a more or less distinctive affective tone. The question arises as to how these afferent sensibilities, which pass through the dorsal thalamus and then by way of the internal capsule to the cerebral cortex, are capable of acquiring emotional coloring. Physiologic results imply that the emotive process is mediated by

the hypothalamus, and anatomic data suggest that it is the mamillary body which sends the excitations to the cortex of the gyrus cinguli.

It has been aptly said that the hypothalamus is the recipient of the vague and undefined impressions from many bodily sources which in their totality represent afferent material capable of influencing the regulative functions of the hypothalamus. It is not yet generally recognized that there are primitive sensory centers in the ventral thalamus, the chief connections of which appear to pass to the hypothalamus. These primitive receptive centers in the ventral thalamus (subthalamus) are known as the pars ventralis of the lateral geniculate body, the nucleus praegeniculatus, the pars ventralis of the medial geniculate body, the reticular nucleus and the nucleus of the mamillary peduncle. These primitive centers receive certain terminals from various afferent systems: For example, the optic tract ends in part in the pregeniculate nucleus and in the pars ventralis of the lateral geniculate body; the acoustic system ends in part in the pars ventralis of the medial geniculate body; the spinothalamic and trigeminothalamic tracts end in part in the reticular nucleus, and the medial lemniscus appears to contribute fibers to the nucleus of the mamillary peduncle.

These nuclei of the ventral thalamus send to the hypothalamus diffuse fiber connections, some of which are better known as the supra-optic decussations. They end in general in the pars optica and the tuber cinereum, the regions which regulate visceral activities and emotional expression. However, the pars optica and the tuber are connected with the mamillary body, which also receives afferent connections through the medial bundle of the forebrain, the mamillary peduncle and the fornix. Thus, the mamillary body is the ultimate recipient of various afferent excitations, which reach the hypothalamus especially through the afferent centers of the ventral thalamus.

It is thus evident that the afferent pathways from the receptor organs split at the thalamic level into three routes, each conducting a stream of impulses of special importance. One route conducts impulses through the dorsal thalamus and the internal capsule to the corpus striatum. This route represents "the stream of movement." The second conducts impulses from the thalamus through the internal capsule to the lateral cerebral cortex. This route represents "the stream of thought." The third conducts a set of concomitant impulses through the ventral thalamus to the hypothalamus and by way of the mamillary body and the anterior thalamic nuclei to the gyrus cinguli, in the medial wall of the cerebral hemisphere. This route represents "the stream of feeling." In this way, the sensory excitations which reach the lateral cortex through the internal capsule receive their emotional coloring from the concurrent processes of hypothalamic origin which irradiate them from the gyrus cinguli.

The aim of the following discussion is to call attention to a number of anatomic regions and their connections, which taken as a whole may be regarded as an integrated mechanism. This, with the aid of clinical data, may be interpreted as subserving the physiologic emotive processes and the psychologic function of emotion itself.

THE HIPPOCAMPAL FORMATION

In an interesting essay, Lewis⁷ has given an account of the history and significance of the term hippocampus, as applied to the cerebral structure first described in the human brain by Arantius, in 1587. Golgi,⁸ in an excellent monograph described and illustrated the fine histologic structure of this region, including the pyramidal cells of the hippocampus and the small granule cells of the fascia dentata.

Ramón y Cajal,⁹ in his unique studies of the histologic structure of the brain, gave an exhaustive and lucid description of the minute structure of the hippocampal formation and its fiber connections, which he included in the olfactory apparatus. Briefly, the main points are as follows: The central olfactory apparatus consists of (1) the olfactory bulb, which is the primary olfactory receptive center, (2) the pyriform (sphenoid) lobe, which is the center of the olfactory perception and (3) the hippocampal formation, which is an association center dealing with the retention and recall of olfactory impressions and their integration with the ideomotor processes of the brain in general. The olfactory nerve terminates in the olfactory bulb. The lateral olfactory tract carries the excitations to the pyriform cortex, terminating there in an external fiber stratum. The pyriform cortex, in particular its posterior part, the angular nucleus (centrum sphenoccipitale or *noyau angulaire*), gives origin to a tract of fibers, the angular bundle (*Winkelstrang* oder *spheno-ammonische Bahn* or *faisceau angulaire ou temporo-ammonique*), which gains an internal position and follows the closed medial angle of the temporal horn of the lateral ventricle, adjacent to the hippocampus—hence its name, the angular bundle. The fibers of this bundle perforate the subiculum of the hippocampal gyrus (*perforierende Fasern* or *fibres perforantes*) and on its external surface form the substantia reticularis alba (Arnoldi), which enters the hippocampal fissure. Here they end in two ways. Part of them synapse with the dendrites of the granule cells of the gyrus dentatus (fascia dentata), and part enter the lacunar

7. Lewis, F. T.: The Significance of the Term Hippocampus, *J. Comp. Neurol.* **35**:213-230, 1923-1924.

8. Golgi, C.: *Istologia normale*, in *Opera omnia*, Milan, U. Hoepli, 1903, vol. 2, chap. 16, pp. 397-536; *Sulla fina anatomia degli organi centrali del sistema nervoso*, *Riv. sper. di freniat.* **9**:1-17, 1883.

9. Ramón y Cajal, S.: *Die Riechrinde beim Menschen und Säugetier*, in *Studien ueber die Hirnrinde des Menschen*, Leipzig, A. Barth, 1900, no. 4. *Histologie du système nerveux de l'homme et des vertébrés*, Paris, A. Maloine, 1909.

layer of the hippocampus. A portion of the angular bundle does not perforate on the same side but passes dorsally to cross in the hippocampal commissure and terminate in the hippocampal formation of the opposite side.

The view is generally held (Ariëns Kappers¹⁰ and others) that the gyrus hippocampi and the fascia dentata are the receptive cortex for this region, while the pyramidal cells of the hippocampus major form the emissive, or motor, layer giving rise to the fornix, or the cortico-hypothalamic tract.

Ramón y Cajal also showed the intimate relation which exists between the posterior portion of the cingulum and the regions from which the angular bundle takes origin. This fiber connection was illustrated schematically by Dejerine (vol. 2, fig. 327),¹¹ showing the intimate relation which exists between the gyrus cinguli and the hippocampal formation. This bundle forms another connection of special interest in regard to the theory of hippocampal functions presented here.

In a mangabey monkey examined by me, from which Professor Dusser de Barenne had removed both temporal lobes, the subcallosal bundles were completely severed. Sections of this brain showed that the cingulum posterior is the largest bundle which enters the medullary core of the gyrus hippocampi. In addition, there was retrograde degeneration of a conspicuous system of association fibers passing from the gyrus cinguli to the temporal lobe. From the gyrus cinguli these fibers pass laterally and ventrally across the internal capsule. In this animal the presence of these degenerated fibers was an obtrusive feature. No previous record of them occurs in the literature.

The subcallosal fasciculus of Muratoff¹² is well known. It lies next the ependyma of the lateral ventricle in the angle formed between the corpus callosum and the caudate nucleus. In the dog and other mammals this bundle can be readily peeled away from the corpus callosum and the lateral wall of the ventricle, and thus its curved course can be traced into the temporal horn, into the region of the angular bundle adjacent to the hippocampal formation. Onufrowicz¹³ first described this fiber stratum as the occipitofrontal fasciculus in the brain of a microcephalic idiot which possessed no corpus callosum to confuse the picture. Bechterew¹⁴ stated that, according to Muratoff, the bundle

10. Ariëns Kappers, C. U.: The Development of the Cortex and the Function of Its Different Layers, *Acta psychiat. et neurol.* **3**:115-132, 1928.

11. Dejerine, J.: *Anatomie des centres nerveux*, Paris, J. Rueff, 1901.

12. Muratoff, W.: Sekundäre Degeneration nach Durchschneidung des Balkens, *Neurol. Centralbl.* **12**:316 and 714, 1893.

13. Onufrowicz, W.: Das balkenlose Mikrocephalengehirn Hofman, *Arch. f. Psychiat.* **18**:305-328, 1887.

14. Bechterew, W.: *Les voies de conduction du cerveau et de la moelle*, Lyon, A. Storck & Cie, 1900, p. 604.

degenerates after lesions of the frontal, parietal and occipital gyri. He stated that Shukowski's experiments on the frontal cortex and the gyrus cinguli (illustrated in Bechterew's¹⁴ book) produced degeneration of this bundle, which was particularly profuse following lesions of the cortex of the gyrus cinguli.

Dejerine,¹⁵ in numerous figures, has illustrated the subcallosal bundle as the *substance grise sous-épendymaire* lying between the caudate nucleus and the corpus callosum. In relation to his *substance grise sous-épendymaire*, he showed the occipitofrontal fasciculus of Forel and Onufrowicz as a special, well myelinated bundle, which extends into the wall of the temporal horn of the ventricle and forms there the tapetum of the sphenoid lobe. In his case,¹⁶ Moriceau (page 148), it degenerated after a frontal lesion.

Mettler¹⁶ (page 532) reviewed the literature and contributed his own observations that lesions of the prefrontal area produce degeneration of the descending and ventral parts of the subcallosal fasciculus. He made this observation:

The posterior component continues backward in dorsal association with the caudate nucleus and makes the return loop with it (into the temporal pole) after sending some fibers to travel more posteriorly beneath the ependyma.

Bechterew and others expressed the belief that the polarity of the bundle is occipitofrontal and that it bears an intimate relation to the caudate nucleus. However, the experimental evidence strongly supports the opposite view that the origin of the subcallosal bundle is frontal, cingular and parietal and that it terminates in a medullary center in the gyrus hippocampi, close to the angular bundle. If this view is correct, the subcallosal bundle and its associated structures constitute another associational link between the general cortex and the hippocampal formation.

The general view of most morphologists, e. g., Ramón y Cajal, Dejerine, Turner and G. E. Smith, has been that the hippocampus, and even the entire limbic lobe, mediate in some obscure way the olfactory sector of functions. The angular bundle is, in fact, of olfactory origin, but it is not the only source of hippocampal incitations. The cingulum posterius brings the cingular gyrus into relation with the hippocampus. Though less important, the subcallosal bundle, including the occipitofrontal fasciculus (tapetum), probably brings the prefrontal region and the gyrus cinguli into functional relation with the hippocampal formation. These make possible the interpretation that central processes from various parts of the cortex may incite hippocampal activity.

15. Dejerine,¹⁵ vol. 2, p. 148.

16. Mettler, F. A.: Cortifugal Fiber Connections of the Cortex of Macaca Mullatta: The Frontal Lobe, J. Comp. Neurol. **61**:509-542, 1935.

For centuries the functional significance of the hippocampus has remained unknown. The hippocampus is by no means a vestigial structure; it may vary greatly in development in different persons. Retzius,¹⁷ commenting on this, stated that the varied development of the hippocampus is independent of age, sex or special prominence of any known psychic function. Ferrier¹⁸ was the first to test the matter experimentally. He destroyed the hippocampus in monkeys and described the depressive effect it produced on cutaneous sensibilities. He expressed the belief that it is the center for these sensibilities. What seems more important now, he described a tendency to somnolence in stating that the monkey was continually tending to drop off to sleep. Subsequent observations have placed the zone of cutaneous sensibility in the parietal lobe, leaving the functions of the hippocampus in obscurity.

Since the Negri bodies, the essential lesions of rabies, or hydrophobia, have their site of predilection in the hippocampus and the cerebellum and since the disease is characterized by intense emotional, convulsive and paralytic symptoms, there seems to be offered an important clue to the probable location of the emotive mechanism. The prodromal symptoms—insomnia, irritability and restlessness—usher in the stage of excitement and profound emotional perturbation. There is extreme hyperesthesia to all forms of stimuli, such as light and sound, and every stimulus situation provokes great apprehensiveness and paroxysms of fear. The patient presents the appearance of intense fright and of mingled terror and rage. Hydrophobia, or fear of water, develops as a result of painful pharyngeal spasms when the patient attempts to swallow fluids. Foaming at the mouth is the common symptom of autonomic disturbance. The predominance of hypothalamic lesions in the supra-optic nucleus has been described by Nicolau and Kopciowska.¹⁹ Wood²⁰ stated:

The Negri bodies are, as a rule, most abundant in the large ganglion cells of the hippocampus major, but occur in ganglion cells of the cerebral cortex and elsewhere.

17. Retzius, G.: *Das Menschenhirn*, Stockholm, P. A. Norstedt & Söner, 1896, vol. 1, p. 67.

18. Ferrier, D.: *The Functions of the Brain*, London, Smith, Elder & Co., 1876.

19. Nicolau, S., and Kopciowska, L.: *Rage du lapin, à virus fixe, et corps de Negri; dénombrement comparatif des inclusions dans la corne d'Ammon et dans la zone élective (noyau optique basal)*, *Compt. rend. Soc. de biol.* **112**:445-448 (Feb. 10) 1933; abstr., *J. A. M. A.* **100**:1190 (April 15) 1933.

20. Wood, F. C.: *Delafield and Prudden's Text-Book of Pathology*, ed. 16, Baltimore, William Wood & Company, 1936, p. 334.

Bassoe and Grinker²¹ (fig. 13) stated that Negri bodies are demonstrable with ease in the ganglion cells of the cornu ammonis and the adjacent temporal lobe. However, they added:

It is important to note that from the appearance of the ganglion cell containing the Negri bodies no more degenerative changes were associated with their presence than in the other ganglion cells.

From such evidence it is possible to construct the hypothesis that the hippocampus participates in some important way in the central production of the emotive process.

THE GYRUS CINGULI

The cortex which borders the corpus callosum on the medial side of each hemisphere is the gyrus cinguli, or the gyrus fornicatus. From the adjacent cortex it is sharply set off by the cingular sulcus. Posteriorly it broadens out into the precuneus, and around the splenium of the corpus callosum it merges with the hippocampal gyrus. Broca assigned the gyrus cinguli to the limbic lobe, and Turner included it in the rhinencephalon. However, as Edinger²² (page 216) remarked, it is a question whether the gyrus cinguli belongs to the olfactory apparatus. Such a grouping, Berry²³ (page 341) said, is arbitrary and misleading, as it is not in accordance with either morphologic or functional fact.

The cyto-architecture of this gyrus has been described by Campbell²⁴ and Ramón y Cajal⁹ and recently by von Economo and Koskinas²⁵ (plate 51). The relations of the fiber bundle, known as the cingulum, to the gyrus have been long recognized. This has been generally interpreted as an association bundle which, according to some authors, is connected with the septal and subcallosal region and, according to others, is more strongly connected to the precuneus and the hippocampal region, through the cingulum posterius.

It was Ramón y Cajal who intimated that the cingulum carries afferent fibers from some unknown source. The recent discovery of an

21. Bassoe, P., and Grinker, R. R.: Human Rabies and Rabies Vaccine Encephalomyelitis: Clinicopathologic Study, *Arch. Neurol. & Psychiat.* **23**:1138-1160 (June) 1930.

22. Edinger, L.: *The Anatomy of the Central Nervous System of Man and of Vertebrates in General*, edited by W. S. Hall, Philadelphia, F. A. Davis Co., 1899.

23. Berry, R. J. A.: *Brain and Mind, or the Nervous System of Man*, New York, The Macmillan Company, 1928.

24. Campbell, A. W.: *Histological Studies on the Localization of Cerebral Functions*, Cambridge, University Press, 1905.

25. von Economo, C., and Koskinas, G. N.: *Die Cytoarchitektonik der Hirnrinde des erwachsenen Menschen*, Berlin, Julius Springer, 1925.

afferent thalamocortical connection from the anterior thalamic nuclei to the gyrus cinguli is to be credited to Clark and Boggon²⁶ and Waller.²⁷ These thalamic connections have been shown by the Marchi and the retrograde cell degeneration technics in the rat and cat. There are indications that in the brain of the monkey similar connections are present (Walker,²⁸ page 30). The course of these fibers has not been illustrated or described in detail. In general they pass laterally and forward from the anterior and anterodorsal nuclei to enter the anterior limb of the internal capsule. They turn dorsally and medially over the anterior horn of the ventricle to enter the cingulum, in the medial wall of the hemisphere. I have observed their degeneration in the rat after injury to the frontal lobe and after incision of the medial wall of the cortex. According to Clark and Boggon and Waller, the connections of the small anterodorsal nucleus are with a small area of cortex of the retrosplenial region, while the anterior nucleus is connected with the extent of the gyrus cinguli. These nuclei also have a strong connection through the inferior thalamic peduncle (*ansa peduncularis*) with the anterior part of the pallidum and by a strong triangular band which passes forward probably with the head of the caudate nucleus. In considering the anterior thalamic nuclei as centers in a functional system, connections with the corpus striatum, as well as with the cingular cortex, must be recognized.—

So far as functions of the gyrus cinguli are concerned, experimental evidence is scant, owing to the inaccessibility of this region. I²⁹ have noted (pages 50 and 72) that in the two sexes the precuneus shows a greater difference in size than any other portion of the cortex, being more highly developed in the male, and it was suggested that representation of the sex organs may be localized there. This difference between the sexes has been confirmed by Mettler³⁰ (page 319) in the brain of the monkey. Sensations related to sex matters possess a high degree of emotional coloring. !!

More important evidence is derived from tumor of the corpus callosum which involves the surrounding cortex. Bristowe³¹ described

26. Clark, W. E. L., and Boggon, R. H.: On the Connections of the Anterior Nucleus of the Thalamus, *J. Anat.* **67**:215-226, 1933.

27. Waller, W. H.: Topographical Relations of Cortical Lesions to the Thalamic Nuclei in the Albino Rat, *J. Comp. Neurol.* **60**:237-269, 1934.

28. Walker, E. A.: An Experimental Study of the Thalamo-Cortical Projection of the Macaque Monkey, *J. Comp. Neurol.* **64**:1-40, 1936.

29. Papez, J. W.: The Brain of Helen H. Gardener (Alice Chenoweth Day), *Am. J. Phys. Antropol.* **11**:29-79, 1927.

30. Mettler, F. A.: Brain of Pithecus Rhesus (M. Rhesus), *Am. J. Phys. Anthropol.* **17**:309-331, 1933.

31. Bristowe, J. S.: Cases of Tumor of the Corpus Callosum, *Brain* **7**:315-333, 1885.

the symptoms of slowly increasing paralysis, impairment of intelligence, progressive drowsiness, profound stupor, coma and death in cases of callosal tumor. Gowers³² (page 712) expressed the opinion that the symptoms of tumor of the corpus callosum are due to pressure on or extension into the cerebral hemispheres. Ironside and Guttmacher³³ illustrated a number of such tumors, which clearly involved the gyrus cinguli of both sides. They stated:

The mental changes which are so commonly present are often the first symptoms. Apathy, drowsiness and defect of memory are met with more commonly than in growths elsewhere, and occur with such regularity in the corpus callosum syndrome as to be characteristic.

Many similar cases can be found in the literature. In a recent paper, Voris and Adson³⁴ described the various symptoms and mental changes in thirty-eight cases. They listed the prominent mental changes as: loss of memory, indifference to environment, change in personality or character, drowsiness, stuporous or comatose state and disorientation in time and place. Less important are *Witzelsucht*, euphoria, puerility, delirium and states of depression. Armitage and Meagher³⁵ listed as first among the mental symptoms loss of spontaneity in emotion, thought and activity. Ligation or occlusion of the left anterior cerebral arteries produces marked reduction of conscious processes. Dandy³⁶ removed the various lobes of the hemispheres and ligated the left anterior cerebral artery and noted the effect on consciousness. He localized the seat of consciousness along the mesial aspect of the left hemisphere and near the corpus callosum. He, in agreement with others, recognized that steadily increasing pressure on the brain stem will produce drowsiness and eventually unconsciousness and postulated conduction tracts between the lower parts of the brain stem and the cortex which are responsible for conscious processes.

Occlusion of the anterior cerebral artery or its branches does not often destroy the gyrus cinguli, and even then rarely bilaterally. Critchley³⁷ described a case (case 2) in which there was softening of the left

32. Gowers, W. R.: *A Manual of Diseases of the Nervous System*, Philadelphia, P. Blakiston's Son & Co., 1888.

33. Ironside, R., and Guttmacher, M.: *The Corpus Callosum and Its Tumors*. *Brain* **52**:442-483, 1929.

34. Voris, H. C., and Adson, A. W.: *Tumors of the Corpus Callosum: Pathologic and Clinical Study*, *Arch. Neurol. & Psychiat.* **34**:965-972 (Nov.) 1935.

35. Armitage, G., and Meagher, R.: *Gliomas of the Corpus Callosum*, *Ztschr. f. d. ges. Neurol. u. Psychiat.* **146**:454-488, 1933; abstr., *Arch. Neurol. & Psychiat.* **33**:1112 (May) 1935.

36. Dandy, W. E.: *Seat of Consciousness*, in Lewis, Dean: *Practice of Surgery*, Hagerstown, Md., W. F. Prior Company, Inc., 1931, vol. 12, p. 57.

37. Critchley, M.: *The Anterior Cerebral Artery, and Its Syndromes*, *Brain* **53**:120-165, 1930.

paracentral lobule and the gyrus cinguli. The initial symptoms were fright, followed by a hysterical fit, semicoma and unconsciousness. As this condition improved, the patient was emotional, irritable and depressed, till the time of her death.

Cogent argument can be drawn from such evidence in support of the view that the gyrus cinguli is the seat of dynamic vigilance by which environmental experiences are endowed with an emotional consciousness. It seems likely that if ever the purely callosal symptoms are separated from the other cortical symptoms, the loss of emotive dynamics will be attributed to the compression or damage of the gyri cinguli, the strong associations of which with the hippocampal formations have already been outlined. There seems to be ample justification for the ancient view of La Peyronie, professor of surgery at Montpellier, who on the basis of such clinical experience expressed the belief that the region of the corpus callosum is the "seat of the soul" (quoted from Critchley³⁷).

THE MAMILLARY BODY

In reptiles the hippocampus is connected with the hypothalamus in a diffuse way through the rudimentary fornix. The mamillary body is still undifferentiated, but this general cellular region is connected with the anterior thalamic nuclei, the connection of which in turn is chiefly with the corpus striatum. One can infer that hippocampal activity, however aroused, influences the hypothalamus in a diffuse way and through the striatal connections regulates attitudes of emotional expression. I³⁸ have suggested (page 469) that in reptiles the anterior nuclei may have an incipient connection with the frontal, parahippocampal cortex, which would correspond in part to the gyrus cinguli of mammals.

In mammals the mamillary bodies as well as the gyri cinguli, with which they connect, are always well developed. Many descriptions of these nuclear masses exist. For the present purpose it may be assumed that the description given by Aronson and me³⁹ (page 10) for the monkey is widely applicable to other forms. A good histologic description is that of Ramón y Cajal.⁹ Cytologic details and connections were given. In brief, the mamillary body consists of a number of nuclei. The medial mamillary nucleus is the largest. The fornix ends chiefly in its lateral part. The larger medial part emits the mamillothalamic tract, or the fasciculus of Vicq d'Azyr. The lateral mamillary nucleus is a triangular mass of large cells in direct connection with the mamillary

38. Papez, J. W.: Thalamus of Turtles and Thalamic Evolution, *J. Comp. Neurol.* **61**:433-475, 1935.

39. Papez, J. W., and Aronson, L. R.: Thalamic Nuclei of Pithecus (Macacus) Rhesus: I. Ventral Thalamus, *Arch. Neurol. & Psychiat.* **32**:1-26 (July) 1934.

peduncle, which, according to the author, is an afferent bundle. This nucleus emits fibers which join the mamillothalamic tract. On the lateral side there also occurs the intercalate nucleus. Dorsally, in the supramamillary decussation is the supramamillary nucleus. A thin layer of cells separates the medial mamillary nuclei of the two sides and extends into the fibrous capsule of the bodies.

—There are at least three direct afferent paths to the mamillary body. In general the capsule receives fibers from the tuber cinereum and the medial bundle of the forebrain, which Ramón y Cajal designated as the *faisceau de la capsule du corps mamillaire interne*. —

The major part of the fornix ends by terminal collaterals in the medial nucleus of the mamillary body. A part of the fornix in some mammals (e. g., the guinea-pig) decussates dorsal to the mamillary body, and a part of this crossed bundle is continued to the interpeduncular region. This caudal bundle is conspicuous in some reptiles (e. g., *Anolis carolinensis*).

The mamillary peduncle may be interpreted as an ascending bundle coming from the region of the medial lemniscus and the medial border of the substantia nigra. In this region I⁴⁰ have identified (page 98) a special nucleus which I have designated as the nucleus of the mamillary peduncle. It appears likely from the observations of Edinger and Wallenberg⁴¹ that the medial lemniscus is related to this structure.

—One can infer that proprioceptive impulses are thus brought into the mamillary body. However, the confusing views on the origin and polarity of the mamillary peduncle reviewed by Ramón y Cajal,⁹ Huber and Crosby⁴² and others must for the present remain an obstacle to any final interpretation of this fiber tract.

—From these connections it is evident that the mamillary body receives impulses from the hippocampus, the tuber cinereum and other sources.

—The mamillothalamic tract, or fasciculus of Vicq d'Azyr,⁴³ is the well known efferent tract from the mamillary nuclei to the anterior and anterodorsal nuclei of the thalamus. Its smaller part arises from the lateral mamillary nucleus. Near its origin the fasciculus bifurcates, giving off a smaller descending mamillotegmental tract, which, according to most authors, terminates in relation to the tegmental nuclei of Gudden. Stimulation along its course gives striking pressor effects, that

40. Papez, J. W.: Thalamic Nuclei of the Nine-Banded Armadillo, *J. Comp. Neurol.* **56**:49-103, 1932.

41. Edinger, L., and Wallenberg, A.: Untersuchungen über den Fornix und das Corpus mamillare, *Arch. f. Psychiat.* **35**:1, 1902.

42. Huber, G. C., and Crosby, E. C.: Somatic and Visceral Connections of the Diencephalon, *Arch. Neurol. & Psychiat.* **22**:187-229 (Aug.) 1929.

43. Vicq d'Azyr, F.: *Traité d'anatomie et de physiologie*, Paris, F.-A. Didot l'Ainé, 1776.

is, rise of blood pressure. As the main mamillothalamic tract ascends, it gives off these collaterals in the region of the nucleus campi Foreli of the Vogts.⁴⁴

It is thus seen that the mamillary body can mass and relay the impulses it receives to the anterior thalamic nuclei and, to a lesser extent, to the deep tegmental nuclei. Kernohan, Learmonth and Doyle⁴⁵ (case 4) reported a case of tumor in the third ventricle which destroyed the tuber cinereum and the corpora mamillaria. The patient was drowsy most of the time; she had diabetes insipidus, and during occasional attacks of weakness she perspired profusely.

The recent work of Ranson,⁴ with the aid of Ingram, showed not only that damage in and around the mamillary bodies causes drowsiness and somnolence in monkeys but that during this period the animals are emotionally inactive. They lost their wildness and even after recovery from somnolence were tame and tractable. When it is remembered that the sensory pathways to the cortex were not interrupted, the importance of the mamillothalamic cortical pathway in insomnia and emotional excitement can be appreciated.

THE ANTERIOR NUCLEI OF THE THALAMUS

How the anterior and the anterodorsal nuclei receive the fasciculus of Vicq d'Azyr and how they connect with the gyrus cinguli, on the one hand, and the head of the corpus striatum, on the other, have already been stated.

Clinical data on the anterior thalamic nuclei are meager, but emotional disturbances, such as spontaneous laughing and crying, from thalamic lesions are well authenticated. Perhaps the most vivid case of compression in this region was described by Penfield⁴⁶ as one of diencephalic autonomic epilepsy produced by a tumor situated at the interventricular foramen, between the anterior thalamic nuclei and back of the column of the fornix.

The patient lay most of the time in obvious pain. At intervals she had an attack in which the same phenomena appeared regularly. The attack was explosive and was confined to the structures controlled by the vegetative nervous system. Prodromal symptoms were restlessness and a request for ice in the mouth, followed by sudden vasodilatation of the area of the skin supplied by the cervical sympathetic nerves. There were sudden rise of blood pressure, lacrimation, salivation, dilatation of the pupils, protrusion of the eyes, increase in pulse rate, retardation

44. Vogt, O., and Vogt, C.: Zur Kenntnis der pathologischen Veränderungen des Striatum und des Pallidum, Sitzungsber. d. k. Akad. d. Wissensch. Math.-naturw. Cl. (Abt. B) **14**:1-56, 1919.

45. Kernohan, J. W.; Learmonth, J. R., and Doyle, J. B.: Neuroblastomas and Gangliocytomas of the Central Nervous System, *Brain* **55**:287-310 (Sept.) 1932.

46. Penfield, W.: Diencephalic Autonomic Epilepsy: The Vegetative Nervous System, *A. Research Nerv. & Ment. Dis., Proc.* **10**:645-663, 1930.

of the respiratory rate, excitability of the pilomotor reflex and loss of consciousness. The attack lasted ten minutes or more. As the symptoms faded, transient hiccup, shivering and respiration of the Cheyne-Stokes type occurred, followed by drowsiness and a tendency to sleep.

Cases of tumors destroying these thalamic nuclei have been recorded. Mott and Barratt⁴⁷ (case 1) described a case in which the tumor involved the anterior thalamic nuclei. Among other symptoms the patient exhibited drowsiness, sometimes falling asleep while taking food. Weisenburg⁴⁸ discussed the question whether lesions of the third ventricle cause mental symptoms, such as apathetic, dull mentality, drowsiness and somnolence. Fulton and Bailey⁴⁹ (case 3) reported a case of hypersomnia due to a cystic tumor of the anterior part of the third ventricle. Hart remarked that "emotional negativism and fatuous serenity are states of mind described by numerous authors." There is little doubt that tumor of this region produces loss of emotive dynamics when it involves the mamillary body, the fasciculus of Vicq d'Azyr or the anterior thalamic nuclei. On the other hand, lesions of the tuber and the pars optica produce diabetes insipidus, Fröhlich's syndrome and other disturbances of the autonomic nervous system, with less marked emotional changes.

THE SUPRA-OPTIC DECUSSATIONS AND THE PARS VENTRALIS THALAMI

The commissures of Meynert, Ganser and Gudden are well entrenched in neurologic literature, though their functional significance is veiled in obscurity. Concerning the origin and ending of these supra-optic decussations the evidence is still conflicting and weighted with the opinions of older authors, e. g., Bechterew,¹⁴ Dejerine,¹¹ Edinger²² and others.

By older authors the origin of Meynert's commissure, as well as its termination, was given as pallidal. So closely are the pallidum and its ansa lenticularis applied to the optic tract that they are superimposed on Meynert's commissure, and it looks as if the commissure arose from the pallidum. Hence the classic view.

Somewhat contrary to this view it has been shown that in some of the lower mammals⁴⁰ (page 94) and in reptiles³⁸ (page 452) what appears to be the equivalent of Meynert's commissure arises from the

47. Mott, F. W., and Barratt, J. O. W.: Three Cases of Tumors of the Third Ventricle, *Arch. Neurol. Path. Lab. London County Asyl. Claybury* **1**:417-439, 1900.

48. Weisenburg, T. H.: Third Ventricle Tumors, *Brain* **33**:236-260, 1910.

49. Fulton, J. F., and Bailey, P.: Tumors in the Region of the third Ventricle: Their Diagnosis and Relation to Pathologic Sleep, *J. Nerv. & Ment. Dis.* **69**:1-25, 1929.

pars ventralis of the lateral geniculate body and the pregeniculate nucleus. Passing along the optic tract, it appears to end in the pars ventromedialis of the supra-optic nucleus. In part it decussates, to end in the hypothalamus of the other side. Accordingly, it represents an afferent connection between the primitive optic centers of the ventral thalamus and the hypothalamus. This point of view has already been indicated by Vonderahe.⁵⁰

In the same papers it has also been intimated that the dorsal supra-optic decussation corresponds to the *fibrae ansulatae*, Ganser's commissure or the anterior hypothalamic commissure in the anterior part of the tuber cinereum. In reptiles these fibers arise from the nucleus of the dorsal supra-optic decussation (Huber and Crosby⁴² and others), situated in the course of the lateral bundle of the forebrain. My own observations on the brains of various mammals (e. g., dog, monkey and man) lead me to believe that the fibers issue in part from a fiber mass situated lateral to the pillar of the fornix, in area P₃ of Winkler,⁵¹ which is interpolated in the course of the oral portion of the pallido-rubro-olivary and other fibers of *ansa lenticularis*. In Carnivora the pallidohypothalamic fibers come from the entopeduncular nucleus, and in the monkey and in man, from a comparable region, namely, the medial nucleus or segment, of the globus pallidus (Grünthal⁵²). I have verified experimentally in the cat that the other coarse fibers of the anterior hypothalamic commissure come from the region of the interstitial nucleus of the midbrain, as described by others.⁴²

Concerning Gudden's commissure, it is generally admitted that its origin is in the inferior colliculus, the posterior portion of the tectum (Huber and Crosby⁴²), and in most lower vertebrates also in the nucleus isthmi or parabigeminal body. En route, as it joins the optic tract, it also receives fibers from the pars ventralis of the medial geniculate body (Papez⁵³ and others). Decussating with the optic tract, it probably ends in the anterior portion of the tuber cinereum, and according to the classic view, many of its fibers may reach the medial geniculate body of the opposite side. Thus, it represents an afferent connection between the primitive acoustic and static centers and the hypothalamus.

50. Vonderahe, A. R.: The Representation of Visceral Function in the Brain, *Ohio State M. J.* **31**:104-109, 1935.

51. Winkler, C.: *Manuel de neurologie. Le corps strié et le diencéphale*, Haarlem, de Erven F. Bohn, 1933, vol. 1, pt. 5, p. 34.

52. Grünthal, E.: Vergleichend anatomische Untersuchungen über den Zellbau des Globus pallidus und Nucleus basalis der Säuger und des Menschen, *J. f. Psychol. u. Neurol.* **44**:403-428, 1932.

53. Papez, J. W.: Evolution of the Medial Geniculate Body, *J. Comp. Neurol.* **64**:41-61, 1936.

As has already been said, it is possible that the mamillary peduncle represents a similar primitive connection of the medial lemniscus, the proprioceptive pathway and of the substantia nigra, to the mamillary body.

Concerning the olfactory centers and the amygdala, the case is simple. The medial bundle of the forebrain connects the septal region and the olfactory tubercle with the whole extent of the lateral hypothalamic nuclei. The stria terminalis connects the amygdala, the function of which is unknown, with the pars optica hypothalami (Johnston,⁵⁴ Krieg⁵⁵ and others).

The question remains how the reticular nucleus and the remaining receptive portions of the pars ventralis thalami are connected with other regions of the brain. Some good evidence was derived from the myelination studies of Bechterew,¹⁴ from the Marchi experiments of Wallenberg⁵⁶ and from the observations of others that ascending spinothalamic and bulbothalamic tracts end in part in these nuclei. The reticular nucleus is generally credited with sending fibers broadcast to the cerebral cortex. Connections with the pallidum and the hypothalamus are possible. What function it mediates is unknown, though its primitive nature is certain. In this regard the thalamic pain syndrome of Dejerine and Roussy⁵⁷ deserves reconsideration, as do the visceral and gustatory functions of the amygdala.

In recent papers of Krieg,⁵⁵ Clark,⁵⁸ Papez and Aronson³⁹ and Walker,²⁸ the connections in the medial walls of the third ventricle have been emphasized. There is no question of the existence of such periventricular fibers, as they can be clearly seen in the brains of reptiles and of most mammals. Especially important are the connections between the medial nucleus and centrum medianum and the hypothalamus. The view of Nathan⁵⁹ on the localization of emotions and personality in the region of the third ventricle appears to have considerable anatomic support. He reviewed the historical development of this idea from

54. Johnston, J. B.: Cell Masses in the Forebrain of the Turtle. *Cistudo Carolina, J. Comp. Neurol.* **25**:393-468, 1915.

55. Krieg, W. J. S.: The Hypothalamus of the Albino Rat, *J. Comp. Neurol.* **55**:19-89, 1932.

56. Wallenberg, A.: Sekundäre sensible Bahnen im Gehirnstamme des Kaninchens, ihre gegenseitige Lage und ihre Bedeutung für den Aufbau des Thalamus, *Anat. Anz.* **24**:142 and 357, 1904.

57. Dejerine, J., and Roussy, G.: Le syndrome thalamique, *Rev. neurol.* **14**: 521-532, 1906.

58. Clark, W. E. L.: Structure and Connections of the Thalamus, *Brain* **55**: 406-470, 1932.

59. Nathan, M.: Le troisième ventricule constitue-t-il un cerveau affectif? *Presse méd.* **39**:857-858 (June 10) 1931.

Haškovec (1910, 1925 and 1929) to Camus (1921, 1924), Roussy and Lhermitte (1924), Rosenfeld (1925) and Küppers (1929).

The left basal region was suspected by Alford.⁶⁰ His observations showed that emotion and consciousness are not located primarily in the lateral cortex of the cerebral hemispheres and that they are more disturbed by basal lesions of the left hemisphere.

SUMMARY

Is emotion a magic product, or is it a physiologic process which depends on an anatomic mechanism? An attempt has been made to point out various anatomic structures and correlated physiologic symptoms which, taken as a whole, deal with the various phases of emotional dynamics, consciousness and related functions. [It is proposed that the hypothalamus, the anterior thalamic nuclei, the gyrus cinguli, the hippocampus and their interconnections constitute a harmonious mechanism which may elaborate the functions of central emotion, as well as participate in emotional expression.] This is an attempt to allocate specific organic units to a larger organization dealing with a complex regulatory process. The evidence presented is mostly concordant and suggestive of such a mechanism as a unit within the larger architectural mosaic of the brain.

Negative and contradictory evidence has not been presented. The structures described here are usually represented as dealing with some phase of the olfactory function. There is no clinical or other evidence to support this view. The new interpretation which I propose can be supported by much more data at present available in the literature, but it is evident that any such doctrine will have to stand the test of experimental and clinical experience if it is to be useful in science. Emotion is such an important function that its mechanism, whatever it is, should be placed on a structural basis.

The organization presented here meets adequately the physiologic requirements proposed by Cannon and Bard in respect to the theory of emotion based on diencephalic-cortical processes. It is also in agreement with the observations of Dandy³⁶ that the seat of consciousness is located somewhere near the midline, between the limits set by the corpus callosum and the basal structures of the brain.

60. Alford, L. B.: Localization of Consciousness and Emotion, *Am. J. Psychiat.* **12**:789-799, 1933.